


Contents lists available at [SciVerse ScienceDirect](http://www.sciencedirect.com)

Manual Therapy

journal homepage: www.elsevier.com/math

Original article

Orofacial manual therapy improves cervical movement impairment associated with headache and features of temporomandibular dysfunction: A randomized controlled trial

Harry von Piekartz^{a,*}, Toby Hall^b^a University of Applied Science, Department of Rehabilitation, Osnabrück, Germany^b School of Physiotherapy, Curtin Innovation Health Research Institute, Curtin University of Technology, Hayman Road, Bentley, Western Australia, Australia

ARTICLE INFO

Article history:

Received 30 June 2012

Received in revised form

22 November 2012

Accepted 18 December 2012

Keywords:

Temporomandibular disorder

Cervicogenic headache

Manual therapy

ABSTRACT

There is evidence that temporomandibular disorder (TMD) may be a contributing factor to cervicogenic headache (CGH), in part because of the influence of dysfunction of the temporomandibular joint on the cervical spine. The purpose of this randomized controlled trial was to determine whether orofacial treatment in addition to cervical manual therapy, was more effective than cervical manual therapy alone on measures of cervical movement impairment in patients with features of CGH and signs of TMD. In this study, 43 patients (27 women) with headache for more than 3-months and with some features of CGH and signs of TMD were randomly assigned to receive either cervical manual therapy (usual care) or orofacial manual therapy to address TMD in addition to usual care. Subjects were assessed at baseline, after 6 treatment sessions (3-months), and at 6-months follow-up. 38 subjects (25 female) completed all analysis at 6-months follow-up. The outcome criteria were: cervical range of movement (including the C1-2 flexion-rotation test) and manual examination of the upper 3 cervical vertebra. The group that received orofacial treatment in addition to usual care showed significant reduction in all aspects of cervical impairment after the treatment period. These improvements persisted to the 6-month follow-up, but were not observed in the usual care group at any point. These observations together with previous reports indicate that manual therapists should look for features of TMD when examining patients with headache, particularly if treatment fails when directed to the cervical spine.

© 2013 Published by Elsevier Ltd.

1. Introduction

Cervicogenic headache (CGH) is a recognized headache subgroup arising from disorder of the cervical spine (Classification Committee of the International Headache Society, 2004). The diagnostic criteria for CGH described by the International Headache Society (IHS) comprises subjectively described complaint patterns, as well as clinical signs of a pain source in the cervical spine. Such clinical signs would include impairment in cervical range of motion (ROM) and pain on palpation of the neck. Indeed these factors have been found to be important in CGH diagnosis (Amiri et al., 2007; Jull et al., 2007).

Although it is recognized that cervical dysfunction is an important contributing factor to CGH, some authors suggest that

temporomandibular disorder (TMD) may also be a contributing factor to CGH pathogenesis in some patients (Leone et al., 1998; Antonaci et al., 2001). Without doubt, there is a close anatomical, functional, and pathophysiological relationship between the cervical spine and TMD. For example, there is evidence that long-term cervical dysfunction may influence the function of the temporomandibular region and vice versa (de Wijer et al., 1996; Nicolakis et al., 2000; Olivo et al., 2006; Bevilacqua-Grossi et al., 2007). As there is significantly greater evidence of TMD in people with headache compared to asymptomatic controls (Glaros et al., 2007) it is possible that in some patients TMD may contribute to the pathogenesis of CGH. Alternatively, headache may be misdiagnosed as CGH when in fact the primary driver may be the temporomandibular joint. In that case, it may be very difficult to differentiate between headache arising from the TMD and true CGH.

Some authors advocate that the same pathophysiologic mechanisms form the basis for different types of headache (Mongini, 2007; Svensson, 2007). For example, TMD was detected in children who suffer from a range of different headache forms (Liljestrom et al., 2005; Bertoli et al., 2007), a similar association was found in

* Corresponding author. Physiotherapy Clinic for Manual Therapy and Applied Neurobiomechanic Science, Stobbenkamp 10, 7631 CP Ootmarsum, The Netherlands. Tel./fax: +31 541294001.

E-mail addresses: hvonpiekartz@googlemail.com, H.von-Piekartz@hs-osnabrueck.de (H. von Piekartz).

adults (Goncalves et al., 2011), potentially suggesting that TMD may contribute to different headache forms. The mechanism behind this may be TMD induced sensitization of the trigeminocervical nucleus; such sensitization is a common factor in different headache forms (Watson and Drummond, 2012). Despite this evidence, it is suggested that in general practice TMD is rarely considered in the management of headache (von Piekartz and Ludtke, 2011).

When TMD is associated with CGH, and the clinical examination features are relevant to the patient's headache complaint, then treatment directed at the TMD may help reduce the CGH symptoms (Von Piekartz, 2007). One explanation for this may be the influence of TMD on upper cervical mobility, and hence CGH. Evidence for the inter-relationship between the upper cervical spine and TMD has been reported (de Wijer et al., 1996; Nicolakis et al., 2000; Olivo et al., 2006). Physiotherapy directed at the cervical spine has been found to be an effective form of management for CGH (Jull et al., 2002; Hall et al., 2007). Likewise, physiotherapy to address TMD together with cervical manual therapy has been found to be effective for patients complaining of chronic headache with some features of CGH and signs of TMD (von Piekartz and Ludtke, 2011).

Although a recent study from our research team has demonstrated the positive benefits of treatment for TMD in patients with headache and mixed features of CGH and TMD (von Piekartz and Ludtke, 2011), no study has investigated the influence of such management on measures of impairment of the cervical spine. Hence the purpose of this study was a secondary analysis of our previously reported randomized controlled trial to investigate whether orofacial physiotherapy treatment has any additional benefit than usual care, in terms of cervical movement impairment, for patients with headache and mixed features of CGH and signs of TMD.

2. Methods

The study design was a randomized controlled trial conducted in accordance with the Helsinki guidelines and approved by the Ethics Committee of the Rehabilitation Centre 'Het Roessingh' in Enschede, The Netherlands. All subjects provided written informed consent.

2.1. Subjects

Subjects were recruited from different physical therapy practices in the Netherlands, comprising 43 patients, either newly referred or currently receiving physiotherapy treatment to the neck (27 women, 18–65 years; mean age 36 ± 7.7 years). All patients were referred to the practices with a provisional diagnosis of CGH by a neurologist. The diagnosis was according to the, without the aid of diagnostic anesthetic blocks and headache pain relief in response to treatment of the cervical spine (hence provisional). Accordingly, subjects had some features of CGH (pain referred from the neck to the head, limitation of neck movement and headache pain on palpation of the upper cervical spine). In addition, subjects were selected if they had the headache for more than 3-months, no prior treatment for TMD, and a Neck Disability Index (NDI) score of more than 15%. Furthermore, subjects were required to demonstrate at least one of four signs of TMD which were based on previously reported criteria (Dworkin and LeResche, 1992): joint sounds, deviation during mouth opening greater than 2 mm (Pahkala and Qvarnstrom, 2004), passive mouth opening range less than 53 mm and pain during passive mouth opening greater than 32 mm on a visual analog scale (VAS) (von Piekartz and Ludtke, 2011). Subjects were excluded if they had received any orthodontic treatment in the past.

As this was a secondary analysis of data from a previously reported randomized controlled trial, the sample size was already determined (von Piekartz and Ludtke, 2011). Fig. 1 illustrates the flow of subjects through the study.

2.2. Procedure

Suitable subjects were randomized into 2 groups by a third researcher using a computerized random number generator. Hence 21 subjects were allocated to the usual care group (mean duration of symptoms $4.6\text{years} \pm 1.2$) and 22 subjects to the orofacial care group (mean duration of symptoms $4.8\text{years} \pm 1.4$). Analysis revealed no significant difference between groups in terms of headache symptom duration and age, with similar gender spread and distribution of signs of TMD.

Three specialist manual therapists with at least 4-years experience in the management of orofacial pain managed the patients in the orofacial treatment group. These therapists had received training at the Cranial Facial Therapy Academy, with 200 h training focusing on the management of craniofacial disorders. The usual care group received cervical spine manual therapy at the physiotherapy clinic they were attending. The 4 treating therapists in usual care group were primary contact practitioners who had more than 5 years of work experience, and who had completed a manual therapy training program recognized by the International Federation of Orthopedic Manual Therapy (IFOMPT). A blinded investigator, with IFOMPT level training and 5 years of post graduate experience, performed 3 assessments of all measures (ROM and manual examination), as follows: before the first treatment, after 6 treatments within a time period of 4–6 weeks, and after 6 months.

2.3. Measurements

Variables assessed that are reported in this study were impairment of the cervical spine ascertained by measurement of cervical ROM in all cardinal planes, the flexion-rotation test (FRT) comprising of rotation in end-range flexion (Fig. 2) to measure upper cervical range of motion, and manual examination of the upper cervical joints.

The Zebris ultrasound system (Zebris CMS 70p system – Zebris Medizin-Technik GmbH, Isny, Germany) was used to measure cervical movements in all planes as well as the FRT. This system has an excellent linear correlation with a precision digital inclinometer (1.0–0.99) (Dvir and Prushansky, 2000). Test–retest and inter-tester reliability has been shown to be good (intraclass correlation coefficient 0.90–0.96, 0.97 and 0.92, respectively) (Malmstrom et al., 2003). The smallest detectable change (SDC) for cervical ROM varies from 6° for lateral flexion to 10° for flexion (Fletcher and Bandy, 2008).

The FRT was performed in supine according to a previously described method which has been shown to be a valid and reliable measurement of upper cervical movement, predominantly at C1/2 (Hall and Robinson, 2004; Takasaki et al., 2010; Hall et al., 2010a, 2010b). The SDC for the FRT is reported as 4 and 7° for left and right rotation respectively (Hall et al., 2010b).

Manual examination, comprising central and unilateral posteroanterior accessory movements (PAM) of the upper three cervical vertebrae, was carried out according to the method described by Maitland et al. (2001). Tests of PAM were performed with the subject lying prone with their neck resting in a neutral position. The examiner applied progressive unilateral posteroanterior pressure to the articular pillars of each vertebra while central posteroanterior pressure was applied to the spinous process of C2 and C3 vertebra. Pain and not local discomfort was rated as present or not. Hypomobility was determined by the therapist, and was based on

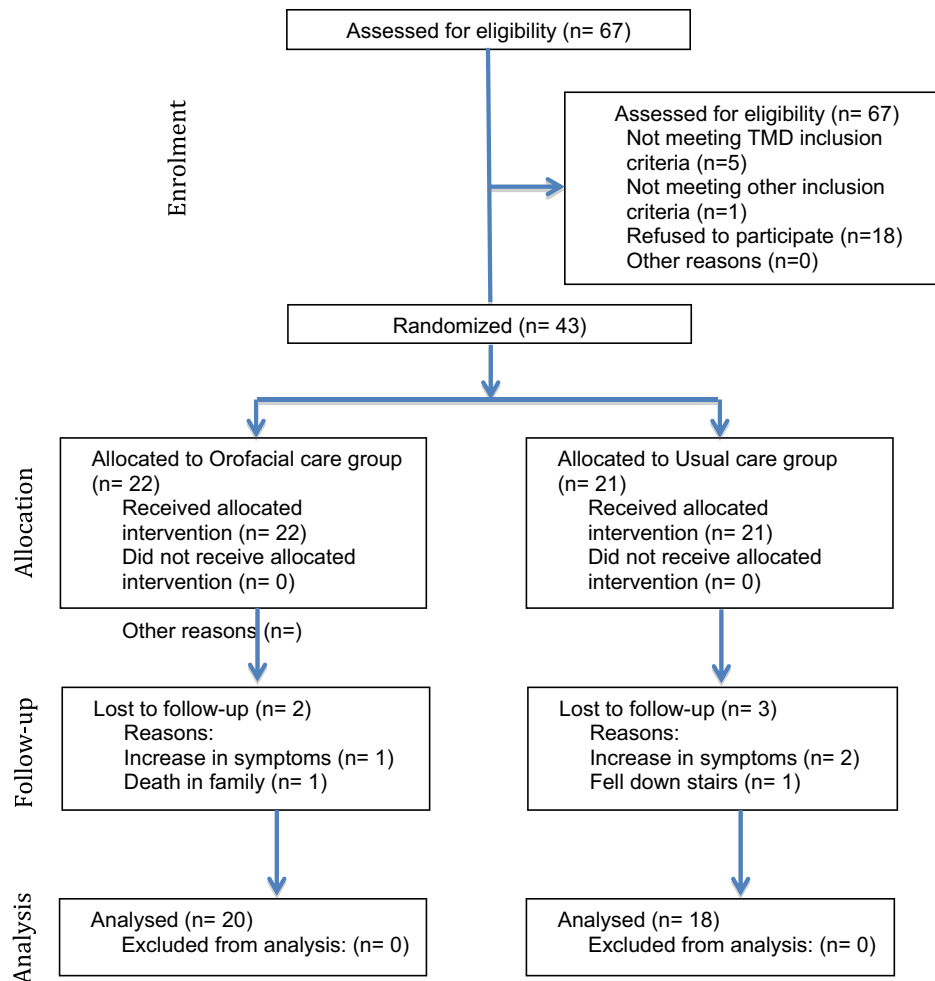


Fig. 1. Flow chart of participants through the study.

side-to-side and level-to-level comparison of resistance to movement, as well as with comparison with expectations based on the therapist's previous experience. Hypomobility was also a dichotomous decision, either present or not. Hypomobility and subjective pain responses to PAM were recorded independently. That is each PAM could be recorded as hypomobile or not as well as painful or

not. The reliability of manual examination has been questioned (Seffinger et al., 2004), but this may be a reflection of poor research methods (Stochkendahl et al., 2006), rather than manual examination being an unreliable procedure. A more recent study with high methodological quality demonstrated good level of reliability for manual examination of the upper cervical spine (Hall et al., 2010c).

The method by which TMD was determined has been detailed in a previous report (von Piekartz and Ludtke, 2011).

2.4. Intervention

Management was based on the clinical examination, and was at the discretion of the treating therapist. Both groups received a total of six 30-min treatment sessions. All six treatment sessions had to be delivered within a minimum of three to a maximum of six week period. In the orofacial care group, treatment followed previously described principles (Von Piekartz, 2007) individualized to the patient. The aim was to address masticatory trigger points, muscle tightness, and temporomandibular joint restriction. In addition and where necessary, techniques to desensitize cranial nerve tissue were also included. Home exercises, individualized to the patient, were also prescribed as required. In 18/20 patients who completed analysis in this group, the therapist provided additional treatment to the cervical region to address cervical components of their disorder. In the remaining 2 patients this additional treatment was not

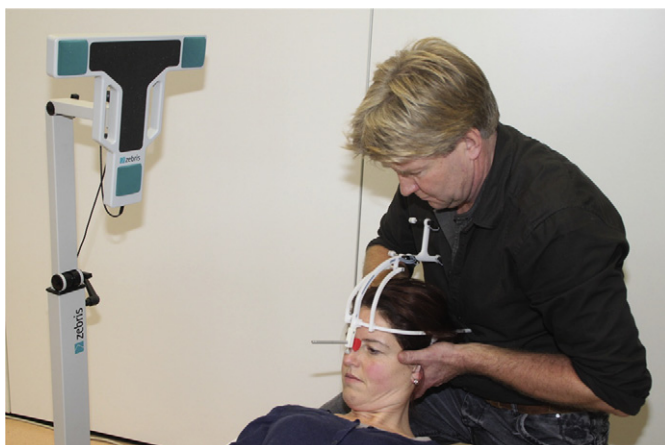

Fig. 2. The flexion-rotation test measured using the Zebris measurement system.

deemed necessary. In contrast, the usual care group received only cervical manual therapy individualized to the patient. This regime included cervical joint mobilization and if necessary high velocity thrusts, muscle stretching and strengthening, and other home exercises (joint ROM, muscle strengthening and stretching) designed for the neck.

2.5. Statistical analysis

The statistical analyses employed in this study were applied to the outcomes taken at the first, second, and third measurements points. This analysis included ANOVA's (with Tukey–Kramer *post hoc* analysis when significant) or Kruskal–Wallis (with Dunn's multiple comparison when significant) or chi-square test. The level of significance was set at 0.05.

3. Results

Fig. 1 shows the flow of subjects through the study. Table 1 shows baseline assessment of each of the four measures of TMD in each group, and the frequency that each sign was positive. When data from both groups were combined, 44.7% of subjects had all four signs of TMD of which 38.9% were in the usual care group and 50.0% were in the orofacial care group. Subjects with at least three signs of TMD were present in 66.7% of the usual care group and 70.0% of the orofacial care group. All subjects had at least two signs of TMD, irrespective of group. No subject presented with a single sign of TMD. The most common sign of TMD was restricted mouth opening with up to 60% of participants having this sign.

Table 2 details mean cervical ROM and change scores with 95% confidence intervals over the 3 evaluation sessions. There was no significant difference between the two groups ($p > 0.05$) at the first measurement session. After 3-months, all cervical movements, bar lateral flexion to the left, were significantly better in the orofacial care group, particularly extension and rotation. In the orofacial care group, between the 3-months and 6-months assessment points, there was less improvement in ROM. This indicates that improvement in cervical movement mostly occurred during the intervention

Table 2

Frequency of pain and hypomobility during manual examination of the upper cervical spine.

Palpated level	Group	Pain			Hypomobility		
		Base	3 Months	6 Months	Base	3 Months	6 Months
C1	Usual care	6	1	0	5	6	4
	Orofacial care	4	0	0	6	3	0
C2	Usual care	27	17	24	30	32	26
	Orofacial care	29	4	1	26	14	8
C3	Usual care	32	11	28	16	22	27
	Orofacial care	30	2	1	23	22	19

period, but only in the orofacial care group. At no point was there a significant change in ROM in the usual care group.

The frequency of the findings of pain and hypomobility during upper cervical manual examination is presented in Table 2. At baseline, the frequency of findings was similar in both groups at each vertebral level. In contrast, pain and hypomobility diminished in the orofacial care group at the second and third assessment point when assessed using PAM. Manual examination was most painful and hypomobile at the C2 and C3 vertebral levels.

The data was analyzed to determine the number of subjects in each group who showed improvement more than the SDC for upper cervical ROM determined by the FRT. This was expressed as a percentage. It was found that 64% of subjects in the experimental group and none in the usual care group improved more than the SDC.

4. Discussion

This study found that the addition of orofacial treatment techniques to usual cervical manual therapy care had beneficial effects over usual care alone for cervical movement impairment in subjects with features of CGH who had impairment of the cervical spine as well as signs of TMD.

Previous research has identified cervical ROM as a sensitive tool to discriminate healthy asymptomatic volunteers from people with

Table 1
Results of range of movement of the cervical spine before, after 3-months and 6-months post-intervention in each group (usual care group $n = 18$, orofacial care group $n = 20$). Mean values (SD), mean change scores and 95% confidence intervals (CI).

	Usual care group			Orofacial care group		
	Baseline Mean (SD)	3 Months Mean (SD) & change scores \pm 95% CI	6 Months Mean (SD) & change scores \pm 95% CI	Baseline Mean (SD)	3 Months Mean (SD) & change scores \pm 95% CI	6 Months Mean (SD) & change scores \pm 95% CI
Flexion	46.7 (11.7)	45.1 (15.7) −1.7 \pm 9.6	46.1 (12.2) 1.1 \pm 9.7	45.2 (15.7)	59 (7.2) 13.75 \pm 6.2 ^a	61.1 (7.6) 2.1 \pm 4.9
Extension	61.1 (8.7)	60.9 (8.6) −0.1 \pm 6.0	59.2 (7.8) −1.7 \pm 5.72	56.8 (12.1)	76.0 (8.5) 19.1 \pm 7.0 ^a	72.6 (7.0) −3.35 \pm 5.5
SF left	35.7 (11.8)	36.7 (11.4) 1.0 \pm 8.07	36.1 (11.8) −0.67 \pm 8.1	32.6 (9.0)	40.1 (7.8) 7.5 \pm 5.6 ^a	48.5 (6.6) 8.5 \pm 4.8 ^a
SF right	42.8 (8.7)	39.7 (8.6) 0.8 \pm 5.9	43.4 (8.5) −0.2 \pm 5.8	39.7 (8.7)	43.9 (6.9) 4.2 \pm 5.2	49.2 (5.1) 5.0 \pm 4.2*
Rot left	60.8 (18.5)	54.0 (18.3) 1.1 \pm 16.6	61.1 (18.0) −0.9 \pm 12.2	54.0 (18.4)	77.4 (8.3) 23.4 \pm 9.4 ^a	78.7 (8.1) 1.3 \pm 5.4
Rot right	54.9 (20.0)	52.2 (18.2) 1.55 \pm 13.6	55.2 (19.8) −1.3 \pm 13.6	52.2 (18.3)	76.5 (10.2) 24.4 \pm 9.8 ^a	79.1 (8.9) 2.6 \pm 6.1
FRT left	23.7 (7.0)	25.8 (6.2) 2.2 \pm 4.6	24.6 (6.2) −1.2 \pm 4.3	22.8 (6.9)	28.5 (3.7) 5.2 \pm 3.6 ^a	30.9 (2.7) 2.3 \pm 2.2 ^a
FRT right	23.3 (8.6)	26.7 (7.3) 3.4 \pm 14.8	24.2 (7.4) −2.5 \pm 5.1	21.7 (8.7)	30.2 (2.1) 8.4 \pm 4.2 ^a	31.13 (2.5) 1.1 \pm 1.6

FRT: Flexion rotation test.

SF: Side flexion.

Rot: Rotation.

^a Indicates significant change from previous assessment point.

CGH (Treleven et al., 1994; Sandmark and Nisell, 1995; Zwart, 1997; Hall and Robinson, 2004; Zito et al., 2006; Jull et al., 2007). Vavrek et al. (2010) identified that CGH and disability were strongly associated with baseline evaluation of active cervical ROM prior to an intervention study. Subjects in the present study clearly had limitation of cervical ROM (including the FRT) at baseline measures. Furthermore, cervical ROM in nearly all planes, improved from baseline evaluation to the 3 month assessment point in participants receiving orofacial treatment. However, this was not the case in participants receiving usual care directed to the cervical spine. These findings taken together with our previous report (von Piekartz and Ludtke, 2011), may appear at odds with other published investigations of cervical manual therapy for CGH (Jull et al., 2002; Hall et al., 2007). However, one explanation for this discrepancy may be that the origin of the headache in the study patients was in fact not the cervical spine, but was in fact the TMD and therefore not a true CGH. This was despite the fact that all subjects fulfilled some aspects of the IHS diagnostic criteria for CGH. The final criteria for confirmation of CGH according to the IHS, is resolution of the headache within 3-months after successful treatment. This clearly did not occur in the usual care group. In contrast, headache resolved with orofacial and cervical spine treatment. This provides further evidence that the source of pain was not the cervical spine and was indeed TMD.

Pain arising from TMD may lead to sensitization of the trigeminocervical nucleus (Goncalves et al., 2011), which may consequently lead to the cervical impairments found in the study patients. Diagnostic criteria for TMD have been published (Dworkin and LeResche, 1992), which have been shown to be valid (Schmitter et al., 2008) and reliable (John et al., 2005). All subjects in this study had at least 2 signs of the previously published diagnostic criteria for TMD (Dworkin and LeResche, 1992), with up to 70% of subjects in the orofacial care group having 3 signs of TMD. Hence the headache diagnosis in these subjects was likely incorrect, and TMD was the cause of headache. It is unclear how many signs of TMD are required to confirm TMD as the cause of headache. However, it would appear that there might be a sub-group of patients presenting with headache who have features of CGH as well as features of TMD (Goncalves, 2012 #3620). However, because of the complex interaction between the cervical spine and TMD (de Wijer et al., 1996; Nicolakis et al., 2000; Olivo et al., 2006) it may be impossible to identify a single pain source, particularly in patients with features of CGH and TMD. As evidenced by this study and our previous report (von Piekartz and Ludtke, 2011), failure to include orofacial care for TMD in patients unresponsive to cervical manual therapy, may lead to treatment failure. Further studies are required to clarify this.

In addition to ROM in the cardinal planes, we found significant improvement in upper cervical ROM identified by the FRT, in subjects receiving additional orofacial treatment but not for those in the usual care group receiving cervical manual therapy. Range improved more than previous reports for the SDC for the FRT (Hall et al., 2010b). There is evidence of the validity of the FRT as a marker of C1/2 dysfunction in people suffering from CGH (Hall and Robinson, 2004; Ogince et al., 2007; Takasaki et al., 2010; Hall et al., 2010a, 2010b). Mean ranges found in the present study are consistent with previous reports (Hall and Robinson, 2004; Hall et al., 2010b, 2010d) in a similar headache population.

The current study findings provide evidence that the FRT has value in assessment and management of people suffering from headache associated with cervical impairment and TMD. This study also provides more evidence that the cervical spine influences the temporomandibular joint and vice versa (Eriksson et al., 2000; Olivo et al., 2006). This evidence, together with evidence from our previous report (von Piekartz and Ludtke, 2011), indicates that combined

orofacial and cervical spine manual therapy is effective in managing features of TMD (Oliver, 2011; von Piekartz and Ludtke, 2011).

In addition to change in cervical ROM, this study found more changes in manual examination findings (pain and hypomobility on PAM) following the intervention in the orofacial care group compared to the usual care group. The spread of manual examination findings possibly indicates a cluster of findings at the C1/2 and C2/3 vertebral levels, which is consistent with previous reports in CGH evaluation (Zito et al., 2006; Hall et al., 2010c).

It was surprising that manual examination findings did not improve as much in the usual care group compared to the orofacial care group. This was despite that fact that both groups received cervical spine manual therapy. The reason for this is not clear from the present study, and requires further investigation. Again the explanation may be that the cervical manual examination findings were secondary to TMD, and improved following orofacial techniques.

There are potential limitations of the present study. Although a neurologist provided a provisional diagnosis of CGH, the diagnostic criteria for CGH were very weak, hence it is probable that TMD was the primary driver of head pain and the cervical spine was secondarily involved. Alternatively, subjects may also have had other headache forms, which were not amenable to cervical manual therapy. Furthermore, patients receiving treatment for CGH were sourced from physiotherapy practices. Hence patients unresponsive to cervical manual therapy may well have been selected for inclusion in this study. Responsive patients may not have been recruited, as they were already improving and therefore not likely to volunteer. An additional limitation is the difference in level of training of the therapists in each group. However the difference in training was in orofacial care, not in cervical manual therapy. Hence, despite the difference in training, the cervical manual therapy would be very similar across each group.

5. Conclusion

Orofacial treatment in addition to usual manual therapy care focussed on the cervical spine was more effective than usual care alone, in improving cervical movement impairment in people suffering from headache with cervical impairment and signs of TMD. These results, when viewed with previous evidence, suggests that people who suffer from headache who have signs of cervical impairment and TMD should receive additional orofacial treatment. Clinicians should examine for features of TMD as part of their examination of patients with headache, particularly when relevant features of cervical impairment do not respond to cervical manual therapy.

References

- Amiri M, Jull G, Bullock-Saxton J, Darnell R, Lander C. Cervical musculoskeletal impairment in frequent intermittent headache. Part 2: subjects with concurrent headache types. *Cephalalgia* 2007;27(8):891–8.
- Antonaci F, Ghirmai S, Bono G, Sandrini G, Nappi G. Cervicogenic headache: evaluation of the original diagnostic criteria. *Cephalalgia* 2001;21(5):573–83.
- Bertoli FM, Antoniuk SA, Bruck I, Xavier GR, Rodrigues DC, Losso EM. Evaluation of the signs and symptoms of temporomandibular disorders in children with headaches. *Arquivos de neuro-psiquiatria* 2007;65(2A):251–5.
- Bevilaqua-Grossi D, Chaves TC, de Oliveira AS. Cervical spine signs and symptoms: perpetuating rather than predisposing factors for temporomandibular disorders in women. *Journal of Applied Oral Science* 2007;15(4):259–64.
- Classification Committee of the International Headache Society. The international classification of headache disorders. 2nd ed., vol. 24. *Cephalalgia*; 2004. Suppl. 1: 9–160.
- de Wijer A, Steenks MH, de Leeuw JR, Bosman F, Helders PJ. Symptoms of the cervical spine in temporomandibular and cervical spine disorders. *Journal of Oral Rehabilitation* 1996;23(11):742–50.

- Dvir Z, Prushansky T. Reproducibility and instrument validity of a new ultrasonography-based system for measuring cervical spine kinematics. *Clinical Biomechanics* 2000;15(9):658–64.
- Dworkin SF, LeResche L. Research diagnostic criteria for temporomandibular disorders: review, criteria, examinations and specifications, critique. *Journal of Craniomandibular Disorder* 1992;6(4):301–55.
- Eriksson PO, Haggman-Henrikson B, Nordh E, Zafar H. Co-ordinated mandibular and head-neck movements during rhythmic jaw activities in man. *Journal of Dental Research* 2000;79(6):1378–84.
- Fletcher JP, Bandy WD. Intrarater reliability of CROM measurement of cervical spine active range of motion in persons with and without neck pain. *The Journal of Orthopaedic and Sports Physical Therapy* 2008;38(10):640–5.
- Glaros AG, Urban D, Locke J. Headache and temporomandibular disorders: evidence for diagnostic and behavioural overlap. *Cephalalgia* 2007;27(6):542–9.
- Goncalves DA, Camparis CM, Speciali JG, Franco AL, Castanharo SM, Bigal ME. Temporomandibular disorders are differentially associated with headache diagnoses: a controlled study. *The Clinical Journal of Pain* 2011;27(7):611–5.
- Goncalves MC, Florencio LL, Chaves TC, Speciali JG, Bigal ME, Bevilacqua-Grossi D. Do women with migraine have higher prevalence of temporomandibular disorders? *Rev Bras Fisioter* 2012.
- Hall T, Briffa K, Hopper D. The influence of lower cervical joint pain on range of motion and interpretation of the flexion–rotation test. *The Journal of Manual & Manipulative Therapy* 2010a;18(3):126–31.
- Hall T, Briffa K, Hopper D, Robinson K. Long-term stability and minimal detectable change of the cervical flexion-rotation test. *The Journal of Orthopaedic and Sports Physical Therapy* 2010b;40(4):225–9.
- Hall T, Briffa K, Hopper D, Robinson K. Reliability of manual examination and frequency of symptomatic cervical motion segment dysfunction in cervicogenic headache. *Manual Therapy* 2010c;15(6):542–6.
- Hall T, Chan HT, Christensen L, Odenthal B, Wells K, Robinson K. Efficacy of a C1–C2 self-sustained natural apophyseal glide (SNAG) in the management of cervicogenic headache. *The Journal of Orthopaedic and Sports Physical Therapy* 2007;37(3):100–7.
- Hall T, Robinson K. The flexion-rotation test and active cervical mobility—a comparative measurement study in cervicogenic headache. *Manual Therapy* 2004;9(4):197–202.
- Hall TM, Briffa K, Hopper D, Robinson KW. The relationship between cervicogenic headache and impairment determined by the flexion-rotation test. *Journal of Manipulative and Physiological Therapeutics* 2010d;33(9):666–71.
- John MT, Dworkin SF, Mancl LA. Reliability of clinical temporomandibular disorder diagnoses. *Pain* 2005;118(1–2):61–9.
- Jull G, Amiri M, Bullock-Saxton J, Darnell R, Lander C. Cervical musculoskeletal impairment in frequent intermittent headache. Part 1: subjects with single headaches. *Cephalalgia* 2007;27(7):793–802.
- Jull G, Trott P, Potter H, Zito G, Neire K, Shirley D, et al. A randomized controlled trial of exercise and manipulative therapy for cervicogenic headache. *Spine* 2002;27(17):1835–43.
- Leone M, D'Amico D, Grazzi L, Attanasio A, Bussone G. Cervicogenic headache: a critical review of the current diagnostic criteria. *Pain* 1998;78(1):1–5.
- Liljestrom MR, Le Bell Y, Anttila P, Aromaa M, Jamsa T, Metsahonkala L, et al. Headache children with temporomandibular disorders have several types of pain and other symptoms. *Cephalalgia* 2005;25(11):1054–60.
- Maitland G, Hengeveld E, Banks K, English K. *Maitland's vertebral manipulation*. London: Butterworth Heinemann; 2001.
- Malmstrom EM, Karlberg M, Melander A, Magnusson M. Zebris versus Myrin: a comparative study between a three-dimensional ultrasound movement analysis and an inclinometer/compass method: intradevice reliability, concurrent validity, intertester comparison, intratester reliability, and intraindividual variability. *Spine* 2003;28(21):E433–40.
- Mongini F. Temporomandibular disorders and tension-type headache. *Current Pain and Headache Reports* 2007;11(6):465–70.
- Nicolakis P, Nicolakis M, Piehlinger E, Ebenbichler G, Vachuda M, Kirtley C, et al. Relationship between craniomandibular disorders and poor posture. *The Journal of Craniomandibular Practice* 2000;18(2):106–12.
- Ogince M, Hall T, Robinson K, Blackmore AM. The diagnostic validity of the cervical flexion-rotation test in C1/2-related cervicogenic headache. *Manual Therapy* 2007;12(3):256–62.
- Oliver M. Temporomandibular joint dysfunction: an open and shut case. *Mobilisation with movement: the art and the science*. Vicenzino B, Hing W, Rivett D, Hall T. Sydney: Elsevier; 2011.
- Olivo SA, Bravo J, Magee DJ, Thie NM, Major PW, Flores-Mir C. The association between head and cervical posture and temporomandibular disorders: a systematic review. *Journal of Orofacial Pain* 2006;20(1):9–23.
- Pahkala R, Qvarnstrom M. Can temporomandibular dysfunction signs be predicted by early morphological or functional variables? *European Journal of Orthodontics* 2004;26(4):367–73.
- Sandmark H, Nisell R. Validity of five common manual neck pain provoking tests. *Scandinavian Journal of Rehabilitation Medicine* 1995;27(3):131–6.
- Schmitter M, Kress B, Leckel M, Henschel V, Ohlmann B, Rammelsberg P. Validity of temporomandibular disorder examination procedures for assessment of temporomandibular joint status. *American Journal Orthodontics Dentofacial Orthopaedics* 2008;133(6):796–803.
- Seffinger MA, Najm WI, Mishra SI, Adams A, Dickerson VM, Murphy LS, et al. Reliability of spinal palpation for diagnosis of back and neck pain: a systematic review of the literature. *Spine* 2004;29(19):E413–25.
- Stochkendahl M, Christensen H, Hartvigsen J, Vach W, Haas M, Hestbaek L, et al. Manual Examination of the spine: a systematic review of reproducibility. *Journal of Manipulative & Physiological Therapeutics* 2006;29:475–85.
- Svensson P. What can human experimental pain models teach us about clinical TMD? *Archives of Oral Biology* 2007;52(4):391–4.
- Takasaki H, Hall T, Oshiro S, Kaneko S, Ikemoto Y, Jull G. Normal kinematics of the upper cervical spine during the Flexion-Rotation Test – in vivo measurements using magnetic resonance imaging. *Manual Therapy* 2010.
- Treleaven J, Jull G, Atkinson L. Cervical musculoskeletal dysfunction in post-concussional headache. *Cephalalgia* 1994;14(4):273–9.
- Vavrek D, Haas M, Peterson D. Physical examination and self-reported pain outcomes from a randomized trial on chronic cervicogenic headache. *Journal of Manipulative and Physiological Therapeutics* 2010;33(5):338–48.
- von Piekartz H, Ludtke K. Effect of treatment of temporomandibular disorders (TMD) in patients with cervicogenic headache: a single-blind, randomized controlled study. *The Journal of Craniomandibular Practice* 2011;29(1):43–56.
- Von Piekartz HJM. *Craniofacial pain: neuromusculoskeletal assessment, treatment and management*. Edinburgh: Butterworth-Heinemann; 2007.
- Watson DH, Drummond PD. Head pain Referral during examination of the neck in migraine and tension-type headache. *Headache* 2012.
- Zito G, Jull G, Story I. Clinical tests of musculoskeletal dysfunction in the diagnosis of cervicogenic headache. *Manual Therapy* 2006;11(2):118–29.
- Zwart JA. Neck mobility in different headache disorders. *Headache* 1997;37(1):6–11.